


비절개법을 이용한 안검하수 교정술

안태주¹, Kenneth K. Kim, M.D.²

아란성형외과¹, UCLA²



Cases of Mild Ptosis Correction with Suture-Method

Tae Joo Ahn, M.D.¹, Kenneth K. Kim, M.D.²

¹Aran Plastic Surgery, Seoul; ²Dream Medical Group and UCLA, California, USA

There are many methods to correct mild blepharoptosis and create double eyelid creases. However, all prior methods have the disadvantages of prolonged swelling, increased recovery time, and the need for an incision when the ptosis correction is simultaneously performed with double eyelid surgery. The authors have devised a new minimally invasive technique to correct mild ptosis during double eyelid surgery. Our technique utilizes stronger suture methods to create double eyelid folds and simultaneously perform the ptosis repair. The correction of mild blepharoptosis is achieved through the transconjunctival Müller's muscle tucking technique during a non-incisional suture method of double eyelid surgery. *(Archives of Aesthetic Plastic Surgery 18: 15, 2012)*

Key Words: Blepharoptosis, Eyelids, Suture techniques, Blepharoplasty

I. INTRODUCTION

The eye is an important feature of the face that gives individuals their overall aesthetic appearance and is an influential factor of one's impression of others. Asians, in contrast with their Caucasian counterparts, typically have smaller eyes and often lack a supratarsal crease, also known as a double eyelid fold. This lack of supratarsal crease causes the hooding of the upper eyelid skin, which can descend to or below the grayline. Therefore, by creating a supratarsal crease, the hooding of the skin is corrected by increasing the surface area of the skin as the skin invaginates inward. This can be accomplished through two methods: the incisional and non-incisional methods. For younger Asian patients without significant excess upper eyelid skin hooding, the non-incisional method is the preferred

technique of surgery by patients. The reason for this is because of its minimal-to-no-scarring effects as only punctures are made for the sutures to pass, allowing for a more natural appearance than the one created by the open incisional technique. Although the suture technique has the negative effect of higher rates of fold loosening over time than the incisional method, it is still the preferred method among patients.

For younger individuals, an aesthetically ideal eye is considered to be one that shows ninety percent of the iris for females and eighty percent for males. When the iris reveals less than the dimensions mentioned above, one may be a candidate for receiving eyelid ptosis correction surgery. Since the vertical palpebral fissure height of Asians is lower than that of their Caucasian counterparts, when less of the iris is shown, they may appear to have a tired or even harsh appear-

Received January 30, 2012
Revised January 30, 2012
Accepted January 30, 2012

Address Correspondence : Tae Joo Ahn, M.D., Aran Plastic Surgery, #2F, Sambo B/D 910-9, Bangbae-dong, Seocho-gu, Seoul 137-842, Korea. Tel: 82-2-3474-2879, Fax: 82-2-3474-2878, E-mail: cmcanti@hanmail.net

안태주 약력

가톨릭의대 졸업
가톨릭의대 성형외과 전공의 수료
대한성형외과학회 눈성형연구회 운영위원 및
간사
가톨릭의대 서울성모병원 외래교수(전임강사)
(현) 아란성형외과 원장

ance Furthermore, the severity of an eyelid ptosis determines its treatment method. Because the eyelid ptosis surgery has a prolonged swelling and recovery period, it has been difficult to recommend ptosis surgery for patients with mild ptosis. However, whether it is for cosmetic purposes or ptosis repair, the correction of subtle borderline eyelid ptosis is gaining acknowledgement and is being more commonly performed among young Asian patients. This article introduces the suture technique for ptosis repair, which can be applied to mild ptosis patients during a non-incisional double eyelid surgery without making the traditional upper eyelid incision. The benefits for this technique are the scarless double eyelid crease formations and eyelid ptosis correction.

II. SURGICAL TECHNIQUE

A) 5-Point 1-Loop Technique

First, the double eyelid crease is made by using a triangular single-knot suture method (Fig. 1). The triangular single-knot suture involves making five small slits or pinhole punctures on the eyelid and numbering the slits from 1 through 5, starting from the medial to the lateral side. The suture is inserted subcutaneously through the 4th slit and passed through the 3rd slit. From the 3rd slit, the suture is passed through the conjunctiva via the 2nd slit. From the 2nd, the suture is passed subcutaneously through the 1st slit. The suture is then passed again through the conjunctiva from the 1st to the 2nd slit. Repeating this pattern back to the original 4th slit completes the overall triangular-shaped continuous suture method. The Müller's muscle tucking is added to this method (Fig. 2). The suture is passed through the conjunctiva from the 3rd to the 4th slit. However, after passing it through

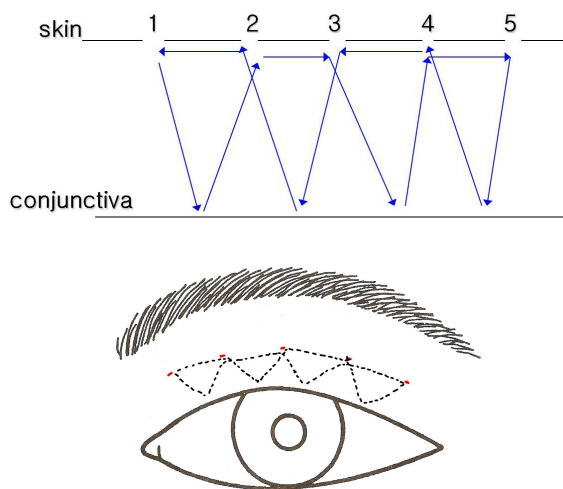


Fig. 1. The triangular single-knot suture method. (Above) External view. (Below) The schematic diagram of the coronal section.

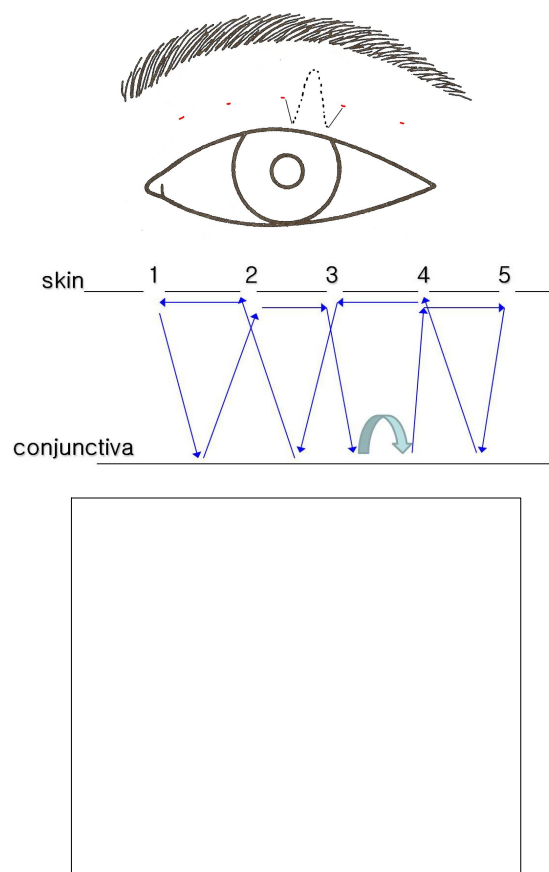


Fig. 2. The Müller's muscle tucking during the process of the suture method double fold surgery (5-point 1-loop method). (Above) The design of the one-loop for the Müller's muscle tucking. (Center) Schematic diagram; the thick arrow indicates the Müller's muscle tucking procedure. (Below) With the traction of the upper margin of the tarsal plate, the Müller's muscle tucking can be conducted without an incision.

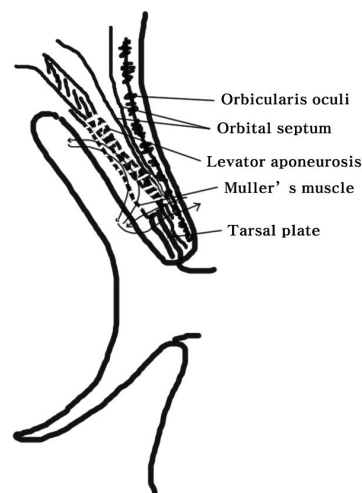


Fig. 3. The Müller's muscle tucking during the process of the suture method double fold surgery are shown in the cross section.

the conjunctiva, the suture does not come out through the skin side, but it is passed through the posterior wall of the conjunctiva in the direction of the Müller's muscle and is elevated approximately 8 to 10 mm cephalad. After heading back down caudally, the Müller's muscle is tucked, and the suture is passed through the skin (Fig. 3).

B) 6-Point 2-Loop Technique

Make six small slits or pinhole punctures on the eyelid skin. A suture is passed from the 5th slit through the conjunctiva and back out to the 6th slit. From the 6th to 5th, the suture is passed subcutaneously. When passing the suture from the 5th slit to the 4th via the conjunctiva, the Müller's tucking is performed. The Müller's muscle tucking is performed by passing the suture approximately 8 to 10 mm cephalad and then passing it back caudally to the upper border of the tarsus plate. The suture is passed subcutaneously from the 4th to the 3rd slit, then through the conjunctiva from the 3rd to the 2nd. Here, another Müller's muscle tucking is performed. The suture is

passed subcutaneously from the 2nd to the 1st slit, then through the conjunctiva from the 1st to the 2nd. Next, the suture is passed subcutaneously from the 2nd to the 3rd slit, then through the conjunctiva from the 3rd to the 4th. Lastly, it is passed subcutaneously from the 4th to the 5th slit, thereby completing the suture method. During these return suture passes, the transconjunctival Müller's muscle tucking can be checked. The protrusion in the conjunctiva and Müller's muscle becomes even and flattens over time so it does not irritate the eyes (Fig. 4).

Case 1

A 27-year-old female desired to undergo the double eyelid surgery. Pre-operative measurements showed her right vertical fissure at 9.0 mm and 7.5 mm on the left. The triangular single-knot continuous suture method was performed on the right eyelid while the Müller's muscle tucking was added on the left eyelid. The eleven months post-operative evaluation showed the right vertical fissure to be 9.0 mm and the left to be 8.5 mm (Fig. 5).

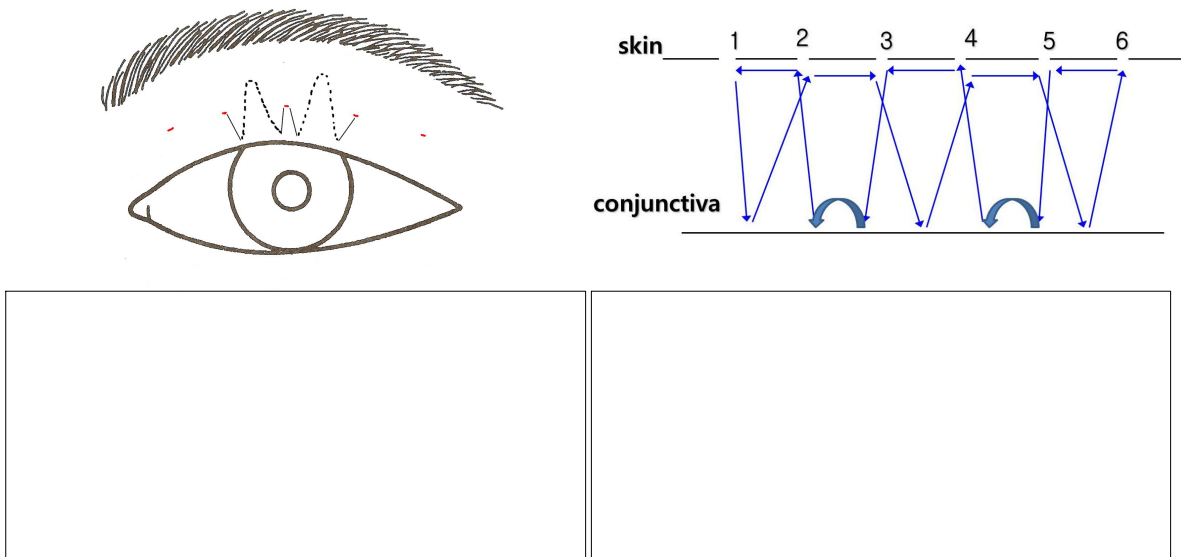


Fig. 4. The Müller's muscle tucking during the process of the suture method double fold surgery(6-point 2-loop method). (Above, left) The design of the two-loop for the Müller's muscle tucking. (Above, right) Schematic diagram; the thick arrow indicates the Müller's muscle tucking procedure. (Below, left) The immediate postoperative photo. (Below, right) 3 weeks later. There is not much widening while the conjunctiva is evened out.




Fig. 5. Case 1. 22-year-old female. Ptosis correction with the suture method (5-point 1-loop). (Left) Preoperative appearance. The left side of the eyelid shows a ptotic state. (Right) Postoperative (11 months) appearance.

Case 2

A 25-year-old female showed the pre-operative condition of 9.5 mm vertical fissure on the right eyelid and 8 mm on the left. The triangular single-knot continuous suture method was performed on the right while the Müller's muscle was added onto the left eyelid. The six months post-operative evaluation showed the right vertical fissure of 9.5 mm and left at 9.5 mm (Fig. 6).

Case 3

A 29-year-old female showed a pre-operative condition of 8.5 mm vertical fissure on the right eyelid and 7.5 mm on the left eyelid. The triangular single-knot continuous suture method was performed on the right eyelid and the Müller's muscle tucking was performed in addition to the suture method on the left eyelid. The six months post-operative evaluation showed her right vertical fissure at 8.5 mm and the left at 8.3 mm (Fig. 7).

Case 4

A 22-year-old male showed a pre-operative condition of the right vertical fissure of 7.5 mm and 6 mm on the left eyelid.

The 6-point 1-loop triangular single-knot continuous suture method was performed on the right eyelid and 6-point 2-loop method was performed on the left eyelid. The post-operative evaluation of 1.5 months showed the right vertical fissure at 9 mm and the left at 8 mm. The post-operative evaluation of 4 months showed a right vertical fissure of 9 mm and 8.5 mm on the left (Fig. 8).

Case 5

A 19-year-old female received a ptosis correction through the 6-point 2-loop method on both her left and right eyelids. The pre-operative measurements showed a vertical fissure of 7.0 mm on both her left and right eyelids (Fig. 4. Below, left photo taken during surgery). The post-operative evaluation of three weeks showed a 8.5 mm vertical fissure on both eyelids (Fig. 4. Below, right). The six months post-operative evaluation showed a right vertical fissure of 9 mm and 9 mm on the left eyelid (Fig. 9).

Case 6

A 31-year-old female received ptosis correction through a 5-point 1-loop method 14 months ago prior to visitation. She




Fig. 6. Case 2. 25-year-old female. Ptosis correction with the suture method (5-point 1-loop). (Above, left) Preoperative appearance. The left side of the eyelid shows a ptotic state. (Above, right) Photo taken with the skin hooding pulled up. (Below, left) Postoperative (2 days) appearance. (Below, right) 6 months post-operation.



Fig. 7. Case 3. 29-year-old female. Ptosis correction with the suture method (5-point 1-loop). (Left) Preoperative appearance. The left side of the eyelid shows a ptotic state. (Right) Postoperative (6 months) appearance.

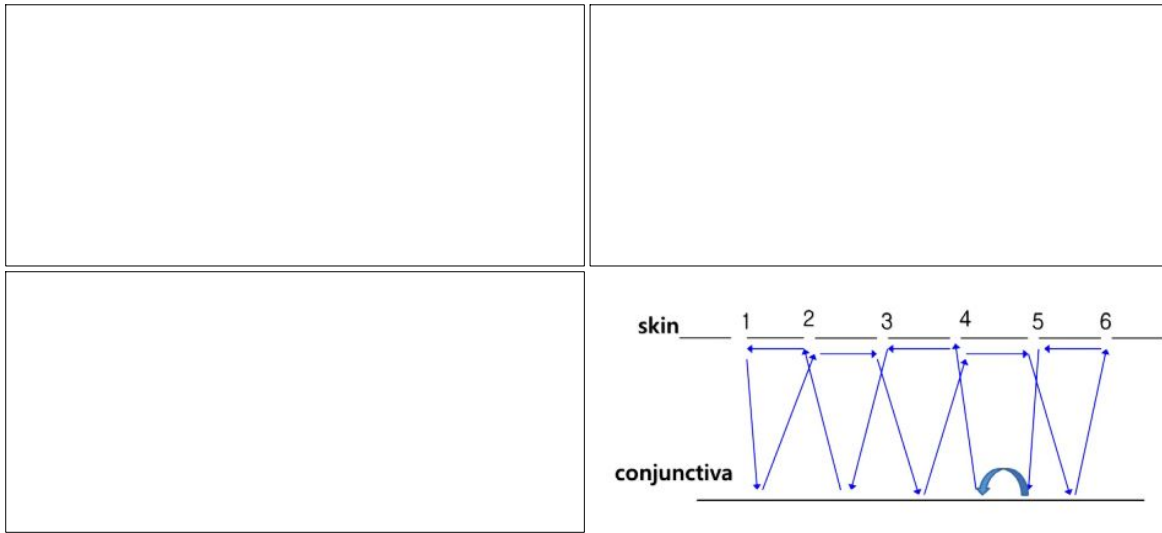


Fig. 8. Case 4. 22-year-old male. Ptosis correction with the suture method. A 6-point 1-loop method performed on the left eyelid; 6-point 2-loop on the right eyelid. (Above, left) Preoperative appearance. The left side of the eyelid shows more of a ptotic state. (Above, right) Postoperative (1.5 months) appearance. (Below, left) Postoperative (4 months) appearance. (Below, right) 6-point 1-loop method.




Fig. 9. Case 5. 19-year-old. Ptosis correction via the suture method (6-point 2-loop). (Above) Pre-operative appearance. (Center) Postoperative (3 weeks) appearance. (Below) 6 months post-operation.

desired a lateral canthoplasty along with the further correction of her borderline ptosis. The 6-point 2-loop method was used to correct her blepharoptosis. The photo during the operation



Fig. 10. Case 6. 14 months after receiving the 5-point-1-loop method. The bottom photo shows that the shortening of the posterior lamella was well-maintained.

shows that the shortening of her posterior lamella was well maintained (Fig. 10).

III. DISCUSSION

The operative method for correcting blepharoptosis varies depending upon its severity and causes. Numerous operative methods have been reported so far. Finsterer¹ categorizes blepharoptosis according to its causes-myogenic, neurogenic, aponeurotic, mechanical, traumatic, and pseudoptosis-and suggests different operative methods optimal for each case.

Some of these operative methods include the conservative technique, Fasanella-Servat technique, Müller's muscle conjunctival resection, Levator advancement, Levator resection, and Brow/frontalis suspension technique. However, most of these operative methods require a considerable amount of incision to be made on the eyelid skin, and have led to the disadvantage of having a prolonged recovery period, swelling, possible hematoma, and scar formation. Other methods do exist that do not require an incision to correct blepharoptosis such as the Fasanella-Servat technique and Müller's muscle conjunctival resection. Yet these methods are more invasive and time-consuming. According to Ayala et al.,² when the conjunctival-Müllerectomy is performed, ptosis correction can be assessed according to the degree of resection. It is suggested that a 10 mm resection be performed in the case of a 2 mm ptosis, 8 mm resection in a 1.5 mm ptosis, and 6 mm resection in a 1 mm ptosis.

For any type of operation, the combination of the simplest method with a minimal recovery period is preferred. Hence, the authors have devised a relatively simple, yet effective method to correct mild blepharoptosis when double eyelid surgery is performed or to reinforce the supratarsal crease. The advantage of our new method is that there is no incision made on the Müller's muscle or levator muscle. Also, the surgery is performed using the same suture used to create the double eyelid fold. The result is less traumatic to the eyelid tissue since no additional surgical incision is made, which also allows for an increased surgical efficiency.

The suture technique has the advantage of creating a scarless double eyelid crease. However, the most common complication is the loss of fold. The traditional suture technique utilizes the 3-point-loop and rectangular shape fixation. However, our method has increased amounts of force (posterior vector). An increased loop formation allows for stronger contact with the dermis to the underlying tarsus, thereby creating a more secure fold formation compared to the traditional method. The resulting fold is sharper and more defined with less of the likelihood of the fold loosening.

The authors propose that a ptosis of 0.5~1.0 mm can be effectively corrected through the 1-loop method and a ptosis of 1.5~2 mm can be corrected through the 2-loop method.

This is a type of mild ptosis case that is difficult to correct with even the traditional open technique (i.e., the levator placcation or levator advancement). This leads to the conclusion that our non-incision, minimally invasive suture technique allows for one to effectively correct these very mild, subtle ptosis cases without having to make an incision, thereby avoiding possible long-term sequela after an open traditional ptosis operation (i.e., levator placcation or levator advancement). The patients have been followed for over two years

and have been without the recurrence of ptosis. Although an incision is not created in order to correct ptosis, we believe that by shortening the muscle with the placcation technique, it will create a scar casting. In effect, this leads to a muscle contracture, which we believe result in permanent muscle shortening.

According to Hirasawa et al.,³ the eye-elevating muscle is composed of voluntary fast-twitch muscle fiber and involuntary slow-twitch muscle fiber. The fast initial voluntary muscle contraction leads to the stretching of the Müller's muscle, which in turn causes involuntary muscles to provide eye-opening strengths in reflex action. The authors propose that when the Müller's muscle tucking is performed, this reflex action is reinforced. As Yoo et al.⁴ and Kim et al.⁵ reported, the non-incisional suture technique has gained immense popularity among young Asian females who desire double eyelid creases. In today's fast-paced society, a surgically effective method for correcting blepharoptosis is needed along with a minimal recovery period. The present method provides a convenient and useful option for the treatment of mild blepharoptosis.

In conclusion, this article introduces the minimally invasive double eyelid surgical technique, in which a permanent suture is used in order to make the double eyelid crease and correct mild ptosis without making an incision. The advantages are minimal to no scarring, quick recovery time, and minimal trauma to the eyelid tissue. Lastly, the advantage of the present method is its technical simplicity and relatively short operating time.

ACKNOWLEDGMENT

The authors declare that they have no conflicts of interest to disclose.

REFERENCES

1. Finsterer J: Ptosis: causes, presentation, and management. *Aesthetic Plast Surg* 27: 193, 2003
2. Ayala E, Gálvez C, González-Candial M, Medel R: Predictability of conjunctival-Müllerectomy for blepharoptosis repair. *Orbit* 26: 217, 2007
3. Hirasawa C, Matsuo K, Kikuchi N, Osada Y, Shinohara H, Yuzuriha S: Upgaze eyelid position allows differentiation between congenital and aponeurotic blepharoptosis according to the neurophysiology of eyelid retraction. *Ann Plast Surg* 57: 529, 2006
4. Ryu HS, Kum IS, Minn KW: Cosmetic Double eyelid surgery. *J Korean Soc Plast Reconstr Surg* 29: 521, 2002
5. Kim YK, Kwon JD, Oh KS: Double Eyelid Operation with three tiny incisions. *J Korean Soc Plast Reconstr Surg* 27: 195, 2000